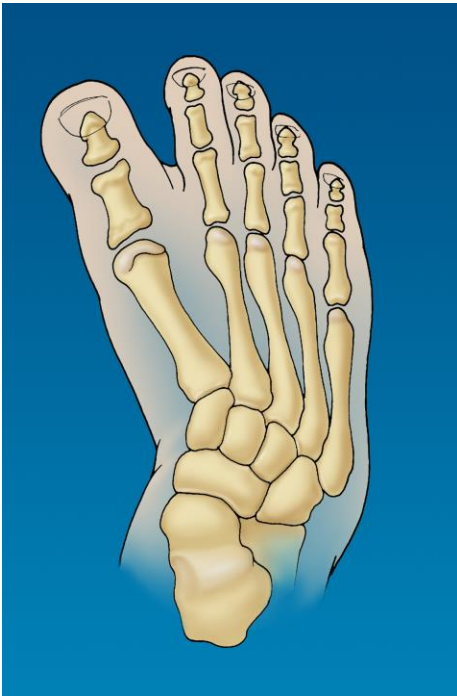


# Skewfoot

A skewfoot is a congenital birth problem in the formation and growth of the bones in the foot. Some doctors will also refer to this as a “Z”-foot, Serpentine foot, or severe metatarsus adductus. Most children have a foot that appears to hook inward or has a “C” shaped appearance. Stretching and orthopaedic shoes may be used until walking. However, the appearance does not improve if the child has a skewfoot.



The diagnosis is difficult to make for several years because of the x-rays. The middle portion of the growing child's foot is more clear gristle and not hard bone on X-ray. Therefore, the exact shape of the bones is not accurately known. By the age of 3-6, the gristle portion has turned into bone. This allows for better interpretation of the x-rays along with MRI imagery.

Some children can be made comfortable with extra wide sneakers and inserts for years. By this age, if shoe wear is ill fitting or there is pain, the parent may consider the surgical option.

The foot deformity consists of 3 parts:

1. *The 5 bones, metatarsals, are turned or hooked inward.*
2. *A bone in the middle of the arch called the 1<sup>st</sup> cuneiform is not shaped like a square, but more like a triangle or trapezoid. This further causes the foot to hook inward.*
3. *The anklebone, heel bone, and navicular bone have shifted out of alignment.*

The surgery involves the cutting of bones, tightening of stretched out ligaments and use of pins and casts. Most children cannot walk on the cast for the first 6 weeks. If x-rays at that time show healing, then a walking cast for 4 weeks is used. The ultimate goal is a child with a flexible foot and able to wear regular sneakers. Maintaining this goal can only be achieved if the congenital deformity does not recur and that the bones grow normally.

